

How do different parts of brain white matter develop after birth in humans?

Sarah Genon^{1,2,*} and Stephanie J. Forkel^{3,4,5,6}

¹Institute for Systems Neuroscience, Medical Faculty, Heinrich-Heine University Düsseldorf, Düsseldorf, Germany

²Institute of Neuroscience and Medicine, Brain and Behaviour (INM-7), Research Center Jülich, Jülich, Germany

³Donders Institute for Brain Cognition Behaviour, Radboud University, Nijmegen, the Netherlands

⁴Brain Connectivity and Behaviour Laboratory, Sorbonne Universities, Paris, France

⁵Centre for Neuroimaging Sciences, Department of Neuroimaging, Institute of Psychiatry, Psychology and Neuroscience, King's College London, London, UK

⁶Departments of Neurosurgery, Technical University of Munich School of Medicine, Munich, Germany

*Correspondence: s.genon@fz-juelich.de

<https://doi.org/10.1016/j.neuron.2022.11.011>

Understanding human white matter development is vital to characterize typical brain organization and developmental neurocognitive disorders. In this issue of *Neuron*, Nazeri and colleagues¹ identify different parts of white matter in the neonatal brain and show their maturational trajectories in line with microstructural feature development.

Our brains harbor approximately 163,000 km of brain connections that orchestrate the emergence of function as we know it.² The thickening of the myelin sheath marks the maturation of these white matter connections. Two other developmental changes include the formation of new connections and the selective pruning of unnecessary connections. This developmental triad is pivotal in facilitating the rapid cognitive and behavioral development in early childhood. For example, the acquisition of language articulation is paralleled by the maturation of the language network.³ Ensheathing the white matter in myelin enables a 100-fold faster propagation of nerve signals. Mapping white matter development in the human brain is, therefore, vital to characterize the typical organization of the young brain and inform our models of neurodevelopmental disorders.

The advent of MRI techniques probing the white matter in the living human brain has enabled the mapping of the connective anatomy in healthy populations (for review, see Thiebaut de Schotten and Forkel²). Studying brain connections across the lifespan has identified changing patterns of maturation: myelin increases in the early years and reduces later in life.⁴ Previous research has demonstrated that white matter myelination happens predominantly after birth,⁴ with critical changes appearing in newborns and infants before the end of the first year. However, the lack of large data-

sets and computational tools has hindered the detailed mapping of local maturational trajectories in the perinatal brain.

Thus far, most studies have been performed in small samples of newborns, challenging the identification of robust patterns specific to the first weeks of *ex utero* life. This limitation has been recently alleviated by the availability of several large datasets, including the developing Human Connectome Project (dHCP), which provides over 700 scans of baby brains.⁵ With such resources, in parallel to methodological advances, it became possible to study brain maturation in early life at a large scale and map general patterns of brain development.

Capitalizing on large-scale neuroimaging data collection in babies, how can we study white matter development in these data? Where in the brain should we focus our attention? How do we define white matter tracts of interest? One possible approach would use brain atlases and regions of interest derived from studying brain organization in adults.⁶ However, by doing so, we impose a specific framework that may obfuscate differential patterns of white matter maturation. An atlas approach would also impede the identification of interindividual maturational trajectories, which might be pivotal in the early stages of behavioral development and related to developmental pathologies. A data-driven approach can be applied to break free from these inherent constraints. In

this case, the whole brain (as opposed to regions of interest) is considered, and the shared variance between different voxels defines different developmental components.⁶

Nazeri and colleagues¹ have recently adopted such an approach. The authors examined the pattern of coordinated maturation of white matter across the neonate brain using non-negative matrix factorization (NMF), a dimensionality reduction method. NMF allows identifying components that show a similar pattern for selected neurobiological features. The method is seductive for neuroimaging data because of its non-negative constraint. In contrast to more traditional factorization approaches, such as principal-component analysis and independent-component analysis, which provide a dimensional score for each voxel on dimensions ranging from negative to positive, NMF facilitates the assignment of voxels to one spatial component. In doing so, NMF decomposes an image into its intrinsic features. Accordingly, the application of NMF to brain voxels promotes a part-based representation of the brain's spatial pattern.

Furthermore, Nazeri and colleagues implemented reproducibility and reliability assessments, in which the similarity of the separation pattern is evaluated across subsamples of participants to ensure the robustness or stability of the factorization pattern.¹ Consequently, such an approach requires a very large sample to



identify a pattern of covariance between voxels across participants and evaluate the generalizability of the derived components across subsamples. The application of such a data-driven approach was made possible by capitalizing on the hundreds of newborns' brain scans available in the dHCP. In their study, Nazeri et al. went one step further by examining the replicability of their subdivision pattern in another large dataset of newborns—the Early Life Adversity, Biological Embedding, and Risk for Developmental Precursors of Mental Disorders (eLABLE).

Nazeri et al. applied NMF to an unconventional T2w/T1w ratio to disentangle patterns of coordinated white matter maturation after birth. The conventional T1w/T2w ratio, which the authors inverted in this study, is considered to estimate myelin in neuroimaging data. White matter connections are initially poorly myelinated in the neonate's brain and appear darker than cortical gray matter.⁷ In other words, the postnatal white matter appears as dark shades of gray on T1 images of newborns in contrast to the brightness that characterizes white matter in toddlers, children, and adults. As such, "it is easier for radiologists (and humans in general) to detect early postnatal white matter structures on T2-weighted images" (personal communication). Consequently, while adult studies use the T1w/T2w ratio,⁸ the authors opted to use an inverted ratio—a T2w/T1w ratio. While inverting the scale is technically correct (both the original and inverted ratios would reflect developmental changes), the comparison between the traditional ratio and the new inverted ratio could deserve some investigations in the future. This is particularly relevant as the inverted metric is anti-correlated with the original T1w/T2w ratio. By capitalizing on the covariance between voxels across the hundreds of participants, NMF summarizes the pattern of coordination in white matter development into relatively homogeneous spatial components. The number of components that best represents the data was defined based on a purely technical standpoint (such as looking at stability across resampling), resulting in nine components (see Figure 1 for an illustration of some components).

The observed subdivision pattern highlights a radial differentiation, where central areas of the brain (close to the ventri-

cles) are distinguished from superficial areas close to the cortex. Between these extremes of this gradient are spatially intermediate components. This gradient aligns with studies showing that myelination starts in central white matter and spreads peripherally during the first year of life (see Gilmore et al.⁷ for a review) and the white matter gradient of variability. Comparing these components to histological data suggests that this organization follows early developmental maturational processes. In this study, the authors show that markers of the subplate extracellular matrix that progressively disappear after birth are less present in the deep global sulcal component than the global gyral component and, in turn, in the superficial prefrontal and temporal pole gyri. In the same vein, myelination markers in *ex vivo* neonatal brains show differences across parts of the brain that are congruent with the separation into different components revealed by NMF in the temporal lobes.

These components emerge from the pattern of coordinated white matter development, raising the question of what differentiates these parts of the brain during developmental trajectories. In other words, how does each part develop in postnatal weeks? Nazeri et al. used statistical modeling (generative additive model) to address this question and map myelination changes across ages. Their analyses mainly show that the deepest global (i.e., unlocalized) component has a relatively soft developmental trajectory, while more localized components show sharper developmental curves (Figure 1, first row). In particular, the periventricular component and components that reach superficial prefrontal regions exhibit a sharp/fast developmental trajectory. Furthermore, most of these components showed delayed development in preterm babies, which is in line with previous findings showing delayed white matter myelination (Figure 1, middle row). Thus, Nazeri et al. demonstrate that myelination is not homogeneous across the postnatal brain and that white matter is spatially differentially affected in preterm babies.

To better understand how microstructural features explain age effects and the impact of preterm birth on myelination, the authors examined finer white matter estimates derived from diffusion MRI.

In term-born babies, neurite density increased across all brain components with increasing age (Figure 1, third row). A lower neurite density was observed in preterm babies, suggesting an association with developmental states. In contrast, neurite orientation dispersion was associated with a lower developmental state in components showing high neurite density. Hence, this potentially reflects the need for pruning parallel to myelination across the first months of *ex utero* life.⁹

In sum, by using a data-driven approach applied to a myelin ratio derived from T2w and T1w scans of newborns provided by the dHCP, Nazeri and collaborators have subdivided the newborn brain into segregated parts that show differential developmental trajectories. These trajectories highlight that some parts have sharp developmental curves. Each component reflects voxel groups that show covariance in their T2w/T1w ratio across newborns. Therefore, one can assume that these components reflect relatively homogeneous regions of white matter maturation. Accordingly, the derived decomposition could serve as a parcellation map for other studies (investigating, for example, white matter alterations in populations at risk of developmental disorders). Nevertheless, before capitalizing on the derived map, one may wonder about the degree of neurobiological validity of this parcellation.

Nazeri and collaborators partially replicated their parcellation in another dataset of more than 200 newborns (the eLABLE data). However, across the two datasets, some regions were merged into relatively homogeneous regions, while others were split into different regions impeding their comparability. Accordingly, although Nazeri et al.'s decomposition offers a useful parcellation, some information may potentially be lost when considering spatially large components. Future studies should also explore finer subdivisions in higher-resolution data to address this potential limitation.

If the parcellation and its characterization provided by Nazeri et al. represent a general pattern of coordinated maturation within specific brain regions at a standard resolution, this parcellation opens the perspective to study alterations at a very early stage in populations at risk of

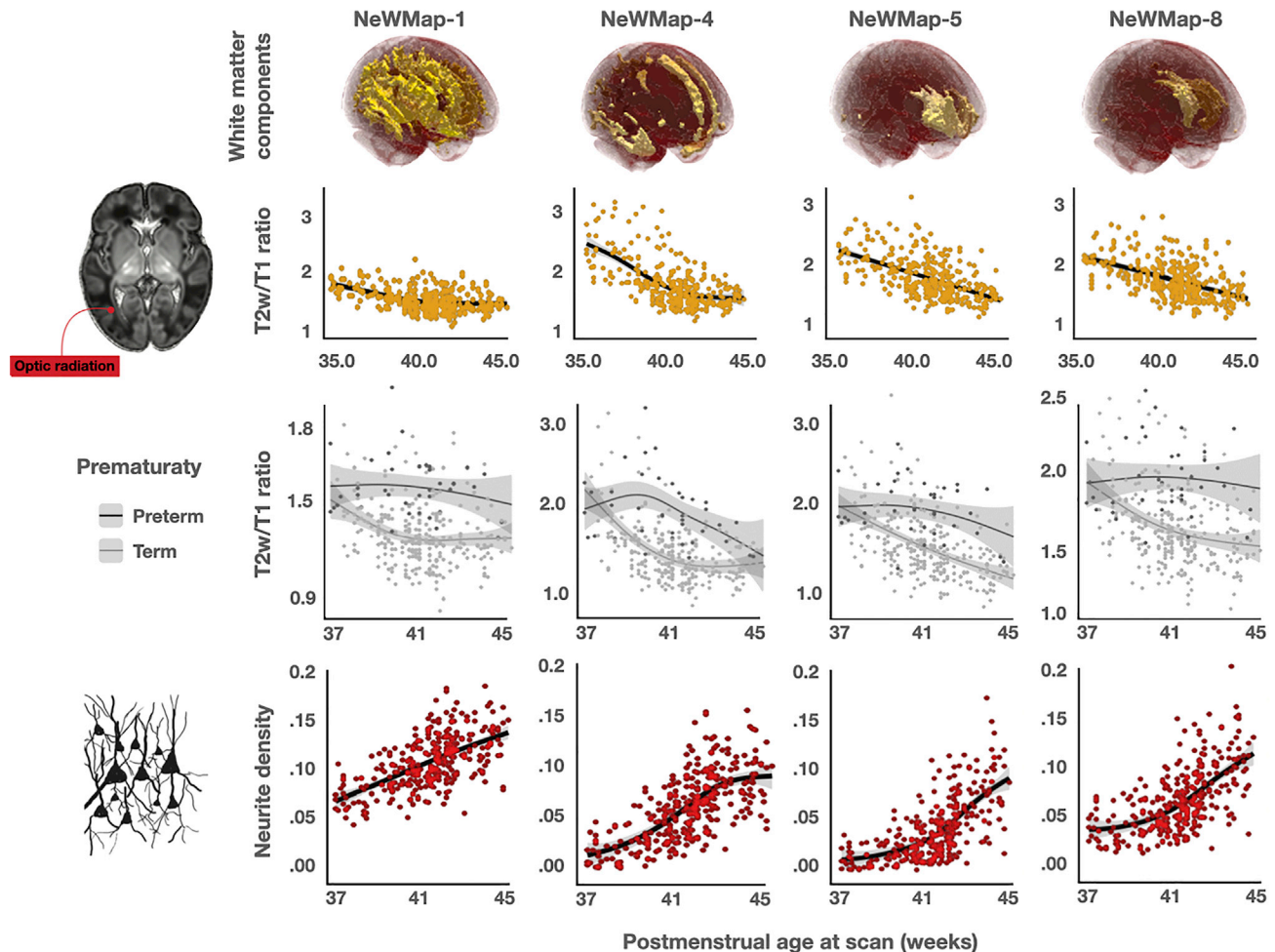


Figure 1. Four of the nine components reported by Nazeri et al. and their developmental characterization

Illustration of the global (unlocalized) deep components (first column), a superficial component, and some more localized components. These components show different white matter maturation trajectories (first row), effects of prematurity (second row), and neurite density (third row). Note that postnatal developmental process generally results in a decrease of T2 and an increase of T1. As such, we can assume that a lower T2w/T1w ratio reflects more myelination (i.e., an increase over time).

developmental disorders. Future longitudinal studies could hence retrospectively investigate developmental patterns for the different components in children who developed disorders such as autism, dyslexia, or ADHD. Furthermore, as white matter shows plasticity properties,⁹ inter-individual variability across the different components could be studied in relation to the exposome. In that regard, it should be noted that using a very large dataset of newborns and data-driven approaches, Nazeri et al. did not find any specific sex effects. These results contradict previous reports from mass-univariate studies suggesting such effects already exist in the fetal brain (e.g., Studholme et al.¹⁰). We may, therefore, wonder when the gener-

ally assumed sex/gender differences in brain structure emerge during development. Another open question is whether similar components could be found in non-human primates and, if so, whether their developmental pattern would be similar to those highlighted by Nazeri et al. Along the same line, the approach used by Nazeri et al. may allow the identification of lateralized components in later developmental stages in humans. Hence, future studies could not only capitalize on this parcellation and characterization to better understand interindividual variability in developmental trajectories, but this approach could be further applied to identify human-specific and/or age-specific co-maturation patterns.

In sum, this paper offers detailed insight into white matter development in the perinatal brain. It potentially opens new avenues to investigate early white matter development to identify children at greater risk of developing neurocognitive disorders.

ACKNOWLEDGMENTS

The authors thank Prof. A. Nazeri, Prof. A. Sotiras, Dr. L. Talozzi, and Dr. A. Beyh for their helpful discussions. This work was supported by the Deutsche Forschungsgemeinschaft (DFG, GE 2835/2-1) and a Donders Mohrmann Fellowship no. 2401515 (SJF, NEUROVARIABILITY).

DECLARATION OF INTERESTS

The authors declare no competing interests.

REFERENCES

1. Nazeri, A., Krsnik, Z., Kostovic, I., Ha, S.M., Kopic, J., Alexopoulos, D., Kaplan, S., Meyer, D., Luby, J.L., Warner, B.B., et al. (2022). Neurodevelopmental patterns of early postnatal white matter maturation represent distinct underlying microstructure and histology. *Neuron* 110, 4015–4030. <https://doi.org/10.1016/j.neuron.2022.09.020>.
2. Thiebaut de Schotten, M., and Forkel, S.J. (2022). The emergent properties of the connected brain. *Science* 378, 505–510. <https://doi.org/10.1126/science.abq2591>.
3. Pujol, J., Soriano-Mas, C., Ortiz, H., Sebastian-Galles, N., Losilla, J.M., and Deus, J. (2006). Myelination of language-related areas in the developing brain. *Neurology* 66, 339–343. <https://doi.org/10.1212/01.wnl.0000201049.66073.8d>.
4. Lebel, C., and Deoni, S. (2018). The development of brain white matter microstructure. *Neuroimage* 182, 207–218. <https://doi.org/10.1016/j.neuroimage.2017.12.097>.
5. Bastiani, M., Andersson, J.L., Cordero-Grande, L., Murgasova, M., Hutter, J., Price, A.N., Makropoulos, A., Fitzgibbon, S.P., Hughes, E., Rueckert, D., et al. (2019). Automated processing pipeline for neonatal diffusion MRI in the developing Human Connectome Project. *Neuroimage* 185, 750–763. <https://doi.org/10.1016/j.neuroimage.2018.05.064>.
6. Eickhoff, S.B., Yeo, B.T.T., and Genon, S. (2018). Imaging-based parcellations of the human brain. *Nat. Rev. Neurosci.* 19, 672–686. <https://doi.org/10.1038/s41583-018-0071-7>.
7. Gilmore, J.H., Knickmeyer, R.C., and Gao, W. (2018). Imaging structural and functional brain development in early childhood. *Nat. Rev. Neurosci.* 19, 123–137. <https://doi.org/10.1038/nrn.2018.1>.
8. Glasser, M.F., Goyal, M.S., Preuss, T.M., Raichle, M.E., and Van Essen, D.C. (2014). Trends and properties of human cerebral cortex: Correlations with cortical myelin content. *Neuroimage* 93, 165–175. <https://doi.org/10.1016/j.neuroimage.2013.03.060>.
9. Dubois, J., Dehaene-Lambertz, G., Kulikova, S., Poupon, C., Hüppi, P.S., and Hertz-Pannier, L. (2014). The early development of brain white matter: a review of imaging studies in fetuses, newborns and infants. *Neuroscience* 276, 48–71. <https://doi.org/10.1016/j.neuroscience.2013.12.044>.
10. Studholme, C., Kroenke, C.D., and Dighe, M. (2020). Motion corrected MRI differentiates male and female human brain growth trajectories from mid-gestation. *Nat. Commun.* 11, 3038. <https://doi.org/10.1038/s41467-020-16763-y>.