

Navigating neuroanatomy

Lilit Dulyan^{a,b,c}, Eva Guzmán Chacón^a, and Stephanie J. Forkel^{a,b,c,d}, ^a Donders Institute for Brain Cognition Behaviour, Radboud University, Nijmegen, the Netherlands; ^b Max Planck Institute for Psycholinguistics, Nijmegen, the Netherlands; ^c Brain Connectivity and Behaviour Laboratory, Sorbonne Universities, Paris, France; and ^d Center for Neuroimaging Sciences, Department of Neuroimaging, Institute of Psychiatry, Psychology and Neuroscience, King's College London, London, United Kingdom

© 2024 Elsevier Inc. All rights are reserved, including those for text and data mining, AI training, and similar technologies.

Introduction	2
Attempted unification	2
Cortex and confusions	3
Connections and confusions	3
Origins of terminology	5
Mythonyms	6
Eponyms	6
Historical-cultural context	7
Conclusion	7
Acknowledgments	7
Funding	7
References	7

Key points

- Evolution of anatomical terminology: Traces the historical evolution of anatomical terminology since the 1895s Basel Nomina Anatomica, highlighting challenges and the impact on contemporary neuroanatomy comprehension.
- One brain but many anatomies: Explores surface, sectional, connectional, and functional anatomy methods, discussing discrepancies in brain lobe definitions and controversies surrounding areas like 'Broca' and 'Wernicke'.
- Cultural and Historical Influences on Nomenclature: Examines how mythonyms, eponyms, and cultural contexts shape anatomical terminology, advocating for updates that reflect modern discoveries and societal inclusivity.
- White Matter and Functional Networks: Discusses the organization of white matter connections and functional systems like the extended language network, emphasizing methodological advances and lingering anatomical misnomers.
- Implications for Language and Cognitive Function: Analyses the impact of anatomical terminology on studying language and cognition, arguing for a nuanced understanding that reflects the complex interplay between brain structure and function.

Abstract

This chapter introduces the origins and development of our current anatomical terminology. It scrutinizes the historical evolution and etymological significance of the over 1900 official anatomical terms in the current nomenclature, underscoring their impact on the contemporary comprehension of cognitive neuroanatomy. The chapter traces unification efforts from the Basel Nomina Anatomica in 1895 to the 1998 Terminologia Anatomica, noting challenges arising from outdated terminology in light of recent anatomical advancements.

Highlighting the influence of terminologies on interpretations of brain anatomy, the chapter explores several anatomical mapping methods such as surface, sectional, connectional, and functional anatomy. It illuminates discrepancies and controversies, exemplified by divergent interpretations of the number of brain lobes and the definitions of 'Broca' and 'Wernicke' areas.

The chapter explores anatomical terms' historical and cultural underpinnings, encompassing mythonyms, eponyms, and cultural influences on nomenclature. It critically examines the implications of these terminologies on contemporary research and shows that Large Language Models mirror these discrepancies. It underscores the need for more inclusive and culturally sensitive approaches in anatomical education.

Lastly, we advocate for updating anatomical nomenclature, suggesting that a deeper understanding of these terminologies could provide insights and aid in resolving ongoing debates in the field. This examination sheds light on historical knowledge and emphasizes the dynamic interplay between language, culture, and anatomy in shaping our comprehension of the neurobiology of the brain and how we navigate neuroanatomy in the 21st century.

Introduction

The nervous system is described using 1933 anatomical terms. This sheer volume of terms contributes to the intricacy of our anatomical language, frequently leading to differences of opinion. Examining these terms' etymological roots and significance is crucial for gaining insight into these debates by comprehending their influence on our contemporary comprehension of cognitive neuroanatomy, with language serving as a particularly compelling illustration.

Attempted unification

The scientific need for simple, stable, and internationally accepted systems for naming anatomical structures has generated many formal nomenclatural systems. In 1895, the Basel Nomina Anatomica aimed to establish the first international nomenclature to resolve confusion and disagreement by reducing the approximately 50,000 terms to 5528 (Eycleshymer, 2018; His and His, 1895). Despite efforts toward unification, some countries published their own revised versions. The first edition of the Nomina Anatomica, 60 years later, replaced the original terminology, retaining most of the terms. In the 1970s, the Latin and English terminology underwent its most recent revision, published as the 1998 Terminologia Anatomica (Marecková et al., 2001) and was last updated in 2011. It is still the authoritative reference for contemporary anatomical terminology with translations in other languages (Sakai, 2007). This edition, hosted by the Université de Fribourg, includes 1933 neuroanatomical terms (<https://ifaa.unifr.ch/Public/EntryPage/HomePublicNew.html>; Fig. 1).

Last updated over a decade ago in 2011, this terminology lacks novel anatomical knowledge. For example, multidisciplinary approaches yield new insights and discoveries while highlighting terminological inconsistencies across subdisciplines. Looking at the different levels of brain anatomy, often using methodologies, highlights the complexity as different terms can refer to the same part of the brain. For instance, surface anatomy focuses on the cortical mantle (e.g. precentral gyrus - surface anatomy, motor cortex/M1 - functional anatomy, BA6 - sectional anatomy; Ono et al., 1990). Sectional anatomy examines cross-sections to locate subcortical nuclei and distinguish between gray and white matter. Connectional anatomy utilizes post mortem dissections or in vivo magnetic resonance imaging tractography to map the brain's pathways in the human brain (Türe et al., 2000; Dziedzic et al., 2021; Catani and Thiebaut de Schotten, 2012; Forkel et al., 2014). Functional anatomy identifies regions based on increased oxygen consumption (e.g. Price, 2012), while cytoarchitectonics categorizes brain areas based on their cellular composition (Amunts et al., 1999). Combining these various mapping techniques in a multimodal multilevel framework has recently been identified as the immediate challenge for the next decade (e.g. the Brain Initiative Project and the Human Brain Project/EBRAINS; Amunts et al., 2024).

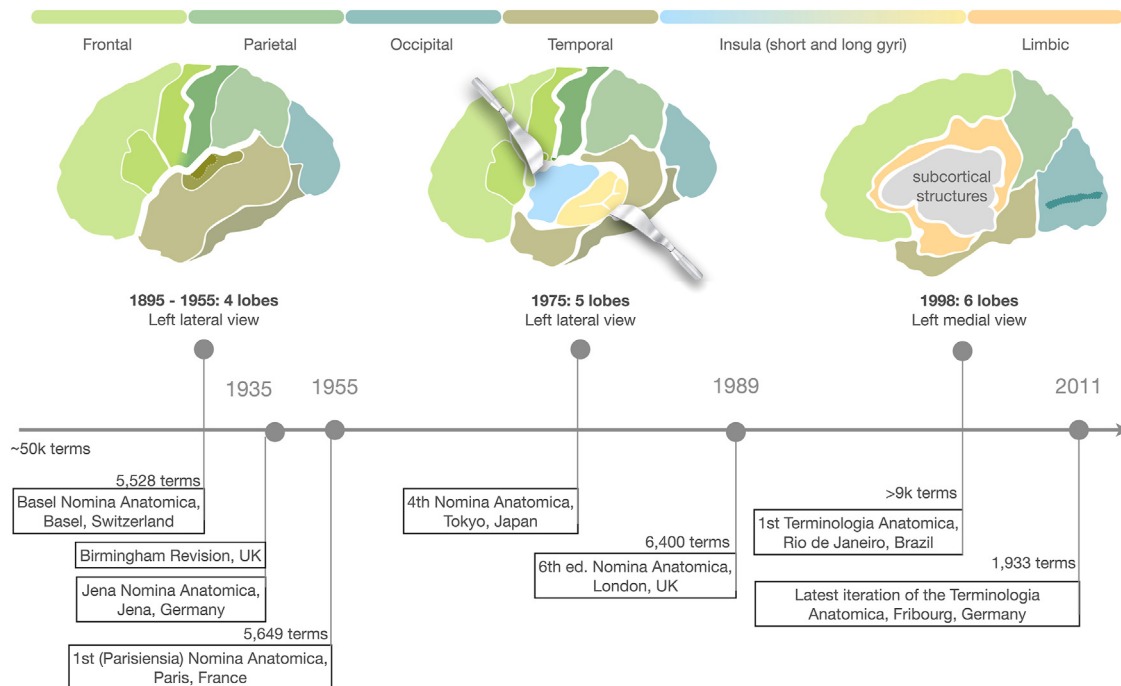


Fig. 1 Evolution of the lobar concept. The official anatomical nomenclature iteratively increased the parcellation to six lobes.

Cortex and confusions

A clear illustration of controversy can be demonstrated with a simple question: *How many lobes does the brain have?*

Groups of neurosurgeons, neuroscientists, students, and members of the public answer this question similarly, with a wide range. When given a choice of digits from 1 to 7, the majority indicates 4 lobes, followed by 5 lobes, while all the other numbers are represented in lower numbers. This variation arises as the correct answer has changed with the evolution of anatomical terminology. Initially, the cortex was divided into four lobes, as established in the Basle Nomina Anatomica in 1895. A significant shift occurred when a later iteration classified the insula as a separate lobe, resulting in five lobes. Subsequent revisions led to the publication of the Terminologia Anatomica (Ribas, 2010), which introduced the limbic lobe, resulting in six lobes (Fig. 1). In the neurosurgical world, the term central lobe also commonly summarizes the pre- and postcentral gyri on the lateral surface and the paracentral lobule on the medial surface (Yasargil, 1994; Frigeri et al., 2015).

According to the official nomenclature, the correct answer should be six lobes. However, the boundaries between the lobes are often arbitrary. For example, if we consider a prominent separating landmark, the central sulcus, that runs between the precentral (frontal lobe) and the postcentral (parietal lobe), it is unclear where exactly this separation should be drawn (e.g. the crown or the depth of the sulcus and anything in between). The parieto-temporal-occipital separation is based on an imaginary T-junction on the lateral surface between the occipital notch (ventrally) and the parieto-occipital sulcus and their connection to the posterior end of the lateral fissure (Fig. 2).

While the lobar division is helpful as a learning tool, its relevance in the clinical realm is limited. The lobar subdivision remains unclear even at the larger level, which is mirrored by Large Language Models (e.g. Gemini (i.e. Bard), ChatGPT; Fig. 3). Querying a search engine returns four or six lobes, depending on the model, when the question was asked, and how often the question is repeated. While these models are not sufficient for anatomical studies, dedicated anatomical AI models trained on correct data might have the potential for a beneficial impact on anatomical education and application.

Additional ambiguity arises when looking at the individual lobes. For example, the canvassing of experts within the Society for the Neurobiology of Language regarding their definitions of “Broca area” and “Wernicke area” revealed significant disparities (Fig. 4A and B; Tremblay and Dick, 2016). The “conundrum papers” published in BRAIN and a reinterpretation of Wernicke area’s anatomical and functional consistency heightened this discussion (Matchin et al., 2022, 2023; Mesulam et al., 2015, 2022). These investigations emphasize the imperative for greater agreement in delineating cortical areas relying on anatomical specificity rather than eponymous labels. This shows that the study of neuroanatomy is not solely an academic exercise but a critical endeavor for having an understanding of critical anatomical features of the brain.

Connections and confusions

White matter pioneers described most known white matter connections during the 19th century using Klingler post mortem dissections (Catani et al., 2010). Theodor Meynert classified them into three main groups: associations (cortico-cortical connections within the same hemisphere), commissural (connecting the two hemispheres), and projections (cortical-subcortical connections). With the advent of in vivo dissection methods (i.e. diffusion-weighted imaging tractography), these groups were replicated and color-coded using RGB maps (red-commissurals, green – associations, blue – projections; Pajevic and Pierpaoli, 1999). Two organizational principles govern the white matter. First, the longer connections run more medially in the brain, while the shorter connections are more superficial. Second, the white matter organization follows a gradient whereby the projections run deep inside the brain, surrounded by commissural connections and associations (Fig. 5). The outmost layer is formed by short U-shaped fibers connecting neighboring gyri.

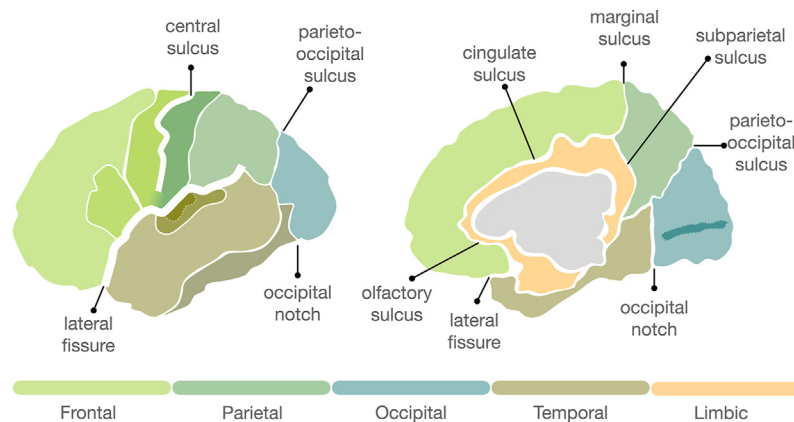
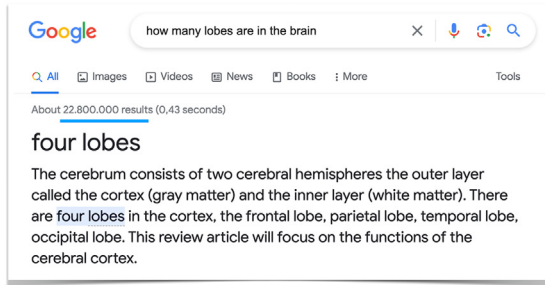
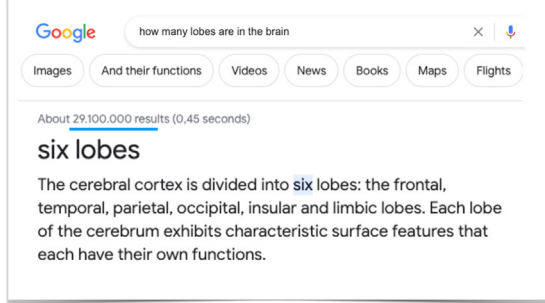


Fig. 2 Sulcal patterns serve as landmarks to separate the lobes (insular lobe not shown) on the lateral (left) and medial (right) surfaces of a hemisphere.

May 2023



September 2023



ChatGPT V3

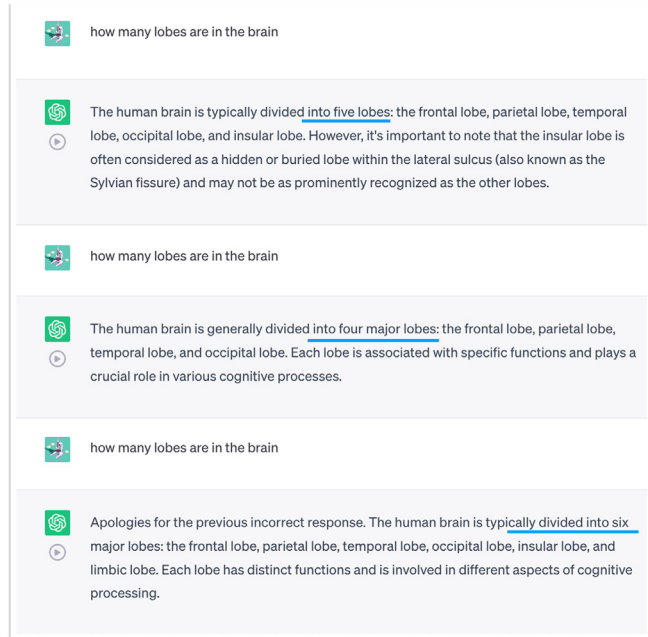


Fig. 3 Google and Large Language Model answer the question “How many lobes are in the brain”. Google initially stated 4 (May 2023) but had updated its answer by September 2023. ChatGPT gave every possible number depending on how often the question was repeated.

The white matter can further be divided into lobar connections or functional systems. One of the most prominent white matter systems is the extended language network beyond the classical arcuate fasciculus. The language network has been divided into a dorsal and ventral system. The primary distinguishing factor between these networks lies in their relative trajectory to the lateral fissure (i.e. above and below; **Fig. 4C**).

The dorsal network encompasses the arcuate fasciculus segments (**Catani et al., 2005**) and the frontal aslant tract (**FAT, Oishi et al., 2008; Catani et al., 2013**). The ventral network comprises the inferior fronto-occipital fasciculus (**IFOF, Forkel et al., 2014**), inferior longitudinal fasciculus (**ILF, Catani et al., 2003**), and uncinete fasciculus (**UC, Catani and Thiebaut de Schotten, 2008**). Despite this categorization, the specific functional roles of these tracts remain unclear (**Forkel et al., 2022**). Moreover, this dichotomization is questionable, given that the cortical projections extend into areas above and below the fissure (**Fig. 4C**). Additionally, the cortical terminations (**Giampiccolo and Duffau, 2022; Fig. 6**) and the volume of a tract vary depending on the

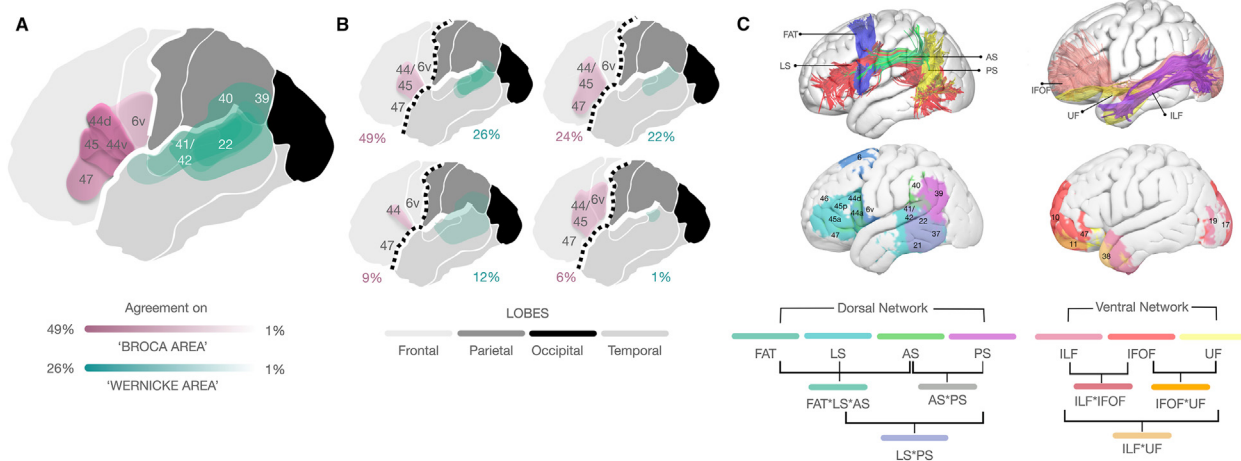


Fig. 4 Dismantling “the” cortical and connective language network. Overall agreement on cortical areas (A) and their composition (B). Exemplified connections of the dorsal and ventral networks (top) and their cortical terminations and overlap (bottom) (C) Human Connectome Project dataset, <https://www.humanconnectome.org/>. FAT, frontal aslant tract; AS, anterior segment of the arcuate fasciculus; LS, long segment of the arcuate fasciculus; PS, posterior segment of the arcuate fasciculus; IFOF, inferior fronto-occipital fasciculus; UC, uncinete fasciculus; ILF, inferior longitudinal fasciculus. (A-B) Data modified from **Tremblay and Dick (2016)**.

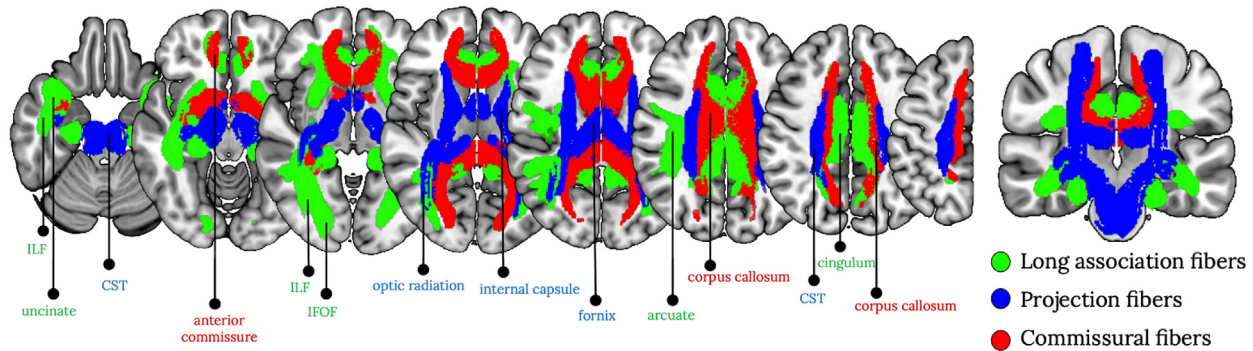


Fig. 5 White matter organization. The figure shows the conventional color-coding and the organizational gradient.

underlying algorithms (Fig. 7). Adding to the complexity is a persistent historical misnaming issue, where the arcuate, which follows a curved fronto-temporal trajectory around the lateral fissure (hence arcuate—arching), has been incorrectly labeled as the fronto-parietal superior longitudinal fasciculus running above the fissure. This misnomer persists in current atlases, amassing erroneous results, particularly with automated methods amplifying inaccuracies in the literature.

Conceptually and methodologically, the ventral network has a complex history (Forkel et al., 2014; Schmahmann and Pandya, 2007). Initial observations indicated interspecies differences where the inferior fronto-occipital fasciculus (IFOF) was visualized in the human brain through postmortem dissections (e.g. Curran, 1909) and tractography (e.g. Forkel et al., 2014), but not observed in the monkey brain using axonal tracing (Schmahmann and Pandya, 2006). Consequently, the IFOF was considered a distinct tract exclusive to humans and speculated to play a role in language processing (Duffau et al., 2005). However, comparative neuroimaging studies have since demonstrated that the IFOF can be visualized in monkeys using tractography (Mars et al., 2016), casting doubt on its uniqueness and exclusive involvement in language-related functions. As such, its precise anatomy and functional role (for language) remain to be clarified.

Neuroanatomy continually advances, underscoring the importance of confirming these discoveries and grasping their clinical implications. Despite discrepancies and diverse approaches, neuroanatomy is indispensable for comprehending cognition and enhancing clinical translation. Investigating the etymology of anatomical terminology offers valuable insights into the historical roots of some disagreements and may contribute to their resolution.

In this chapter section, we shed light on the etymology of our current anatomical terminology, drawing upon both documented sources and compelling anecdotes from the world of anatomy. For instance, we explore the origin of the term “temporal lobe,” which derives its name from the bone that overlies this area of the brain. Interestingly, the bone itself is named after the Latin word for time (“Tempus”), reflecting an observation that the hair covering the temporal bone tends to turn gray first in man as they age, symbolizing the passage of time.

Origins of terminology

The standardized nomenclature combines Latin and Greek roots, allowing for the description of brain structures in three-dimensional space. Favoring the orthograde (i.e. upright) orientation leads to a definition of what is in front (anterior), behind

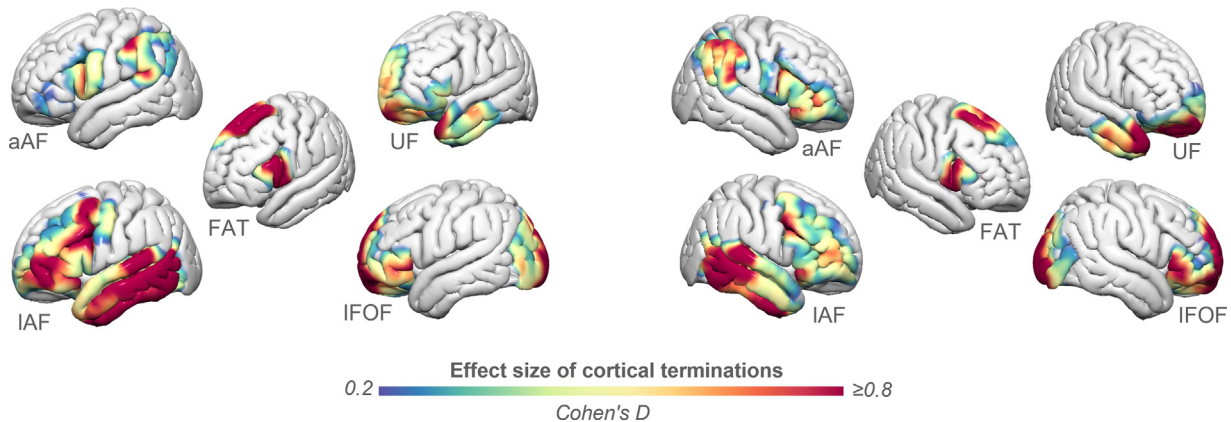


Fig. 6 Cortical projections of the dorsal and ventral language network. aAF, anterior segment of the arcuate fasciculus; IAF, long segment of the arcuate fasciculus; FAT, frontal aslant tract; UF, uncinata fasciculus; IFOF, inferior fronto-occipital fasciculus.

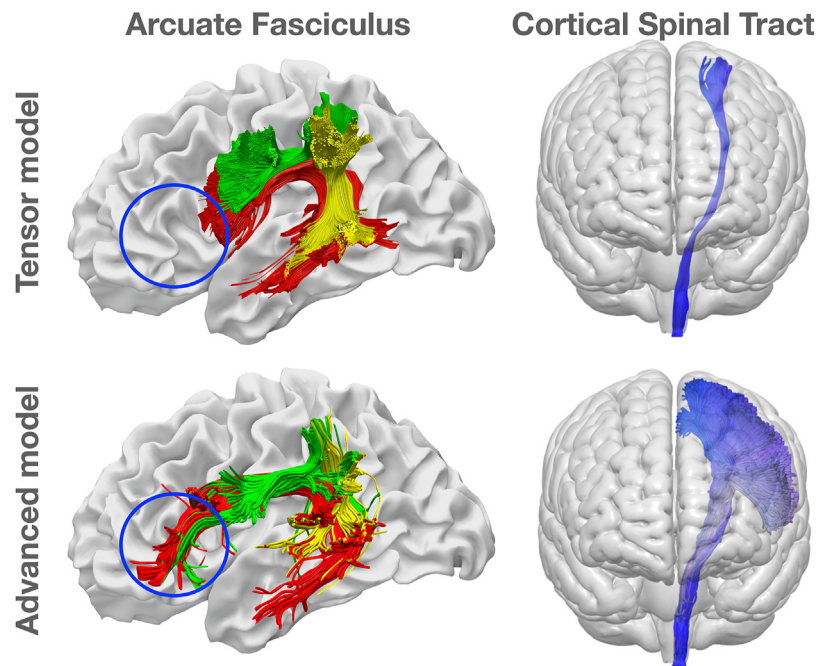


Fig. 7 Different algorithms and their cortical and volumetric differences for the language (arcuate fasciculus) and motor system (cortical spinal tract). Modified from Beyh A, Ohlerth AK & Forkel SJ. Harnessing Advanced Tractography in Neurosurgical Practice. In: Krieg & Picht, (Eds.), Navigated Transcranial Magnetic Stimulation in Neurosurgery, in press, <https://osf.io/preprints/psyarxiv/emhrn>.

(posterior), above (superior), below (inferior), toward the center (medial) and the surface (lateral). Prefix modifiers such as sub (beneath in Latin; e.g. subcentral meaning under the central sulcus), hypo (under in Greek; e.g. hypothalamus), supra (above; e.g. supratentorial), inter (between; e.g. interthalamic adhesion), pre (before; e.g. precentral), and post (after; e.g. postcentral), peri (around, e.g. perisylvian meaning around the Sylvian fissure), further specify anatomical relationships. Additionally, some structures are named associatively (e.g. the hippocampus - seahorse), color-based (e.g. locus caeruleus - blue spot), shape-based (e.g. arcuate - arch), or descriptive (e.g. perforated substance). Anatomical landmarks and pathologies are also named after mythical (mythonyms) and historical figures (eponyms), cities (e.g. Nijmegen Breakage Syndrome, [Chrzanowska et al., 2012](#)), or based on their historical-cultural contexts.

Mythonyms

In general anatomy, mythonyms abound (e.g. Achilles tendon, Atlas vertebra; [Karenberg, 2013](#)). An estimated 30 medical terms originate from mythology ([Kucharz, 2020](#)). Mythonyms are, however, not commonly employed in neuroanatomy, albeit in psychiatry (e.g. panic from the God Pan or chronic from the titan Cronos; [Naznean, 2021](#)).

Eponyms

Honoring or commemorating individuals by associating their names with structures or procedures has been customary. Until the 19th century, many anatomy pioneers were bestowed with this honor, leaving few opportunities for women to attach their names to anatomical structures. In 1849, Elizabeth Blackwell became the first recorded woman to complete a medical degree when most anatomical eponyms had already been established. A famous and controversial medical eponym dedicated to a woman is the immortal “HELA” cell line ([Henrietta Lacks, 2020](#)). In neuroanatomy, numerous examples of eponyms named after male anatomists exist, such as the circle of Willis, the island of Reil, and the Sylvian Fissure (see for more www.whonamedit.com; [Burdan et al., 2016](#)). Neurological and psychiatric disorders have also been named after the individuals associated with their initial identification. Examples in neurology include Broca and Wernicke aphasias, Alzheimer disease, Parkinson disease, Huntington disease, and a recent addition, Schmahmann Syndrome. This is not an exhaustive list, as there are over 45 eponymous neurological disorders and many brain structures and procedures. Other related fields boost even longer lists, such as psychiatry, with some examples including Capgras syndrome, Charles Bonnet syndrome, Gerstmann syndrome, and Munchausen syndrome (see for more examples [Bresch, 2002](#)).

Recognizing the limitations and biases inherent in eponymous descriptions, recent initiatives have shifted their focus toward standardized anatomical definitions. This shift aims to challenge historical biases and encourage critical reconsiderations of prominent figures (see also [Boraud and Forkel, 2022](#)). One of the goals is to provide access to descriptive anatomical terminology, promoting the process of de-eponymification (<https://litfl.com/eponym/de-eponymification>). Efforts like the Open Access Library of Inclusive Anatomical Science Learning Resources aim toward fostering more inclusive and culturally sensitive approaches to

anatomical education. These endeavors acknowledge the necessity of revising and reframing terminology to reflect diverse perspectives.

Historical-cultural context

The final terminology group highlights the cultural influences that have been pivotal in shaping anatomical nomenclature. For example, early anatomists, perceiving the thalamus as a contained structure with the fornix resembling its roof, drew parallels to concepts such as a bridal bed or an inner sanctuary. Within the thalamus, the largest nucleus received the name pulvinar, alluding to its “pillow-like” shape within this figurative “bridal bed.” Deep within the brain, the fornix connects the hippocampus to the mammillary bodies (translating to “small breasts”), which connect to the thalamus through the mamillothalamic tract. Fornix describes a “dome-shaped” architectural structure and is applied to the cerebral and vaginal fornix alike. Notably, the fornix’s resemblance to the clitoris’ anatomy is not coincidental. This connection between anatomy, sex, and architectural terminology goes back to ancient Rome. In that historical context, the term fornix purportedly became associated with areas near the city’s gates where prostitutes would congregate (referred to as “fornices” in plural form). Consequently, the term gradually became linked with prostitution and eventually with fornication, initially denoting individuals who frequented brothels before extending to encompass extramarital sexual relations.

Exploring these anatomical terms unveils the intricate interplay between anatomical observation and societal context. It underscores how the cultural-historical perspectives of their times have significantly shaped our understanding of the human body, and these influences are still discernible in today’s anatomical terminology.

Conclusion

In conclusion, exploring terminological origins reveals insights into historical knowledge, highlighting the interplay between language, culture, and anatomy. Concerns have driven crucial changes, such as the World Health Organization’s recommendation against possessive language (Ayesu et al., 2018) and the International Federation of Associations of Anatomists’ opposition to eponyms. In this digital age, where much research relies on atlases and automatic methods, it is valuable to reflect on our field’s history, embrace recent advancements, and anticipate future challenges.

Acknowledgments

We thank Andrea Martin, Peter Hagoort, Edward Chang, James McQueen, and Simon Fisher, whose engaging discussion on anatomical terminology during a dinner inspired this paper (Nijmegen, May 2023). We also thank Willem Blok for his enlightening lecture, “The language of doctor-patient interactions” (Gouda, May 2023), which was a valuable source of inspiration. We are greatly indebted to the CNS and BCB teams for discussions, especially Ahmad Beyh and Michel Thiebaut de Schotten, and to the 2023 Neuroanatomy students at Radboud UMC.

Funding

This project received funding from the Donders Theme Leadership Award (SJF, LANGUAGE & COMMUNICATION) and the Donders Mohrmann Fellowship No. 2401515 (SJF, NEUROVARIABILITY).

References

- Amunts, K., Axer, M., Banerjee, S., Bitsch, L., Bjaalie, J.G., Brauner, P., et al., 2024. The coming decade of digital brain research: A vision for neuroscience at the intersection of technology and computing. *Imaging Neurosci* 2, 1–35. https://doi.org/10.1162/imag_a_00137.
- Amunts, K., Schleicher, A., Bürgel, U., Mohlberg, H., Uylings, H.B., Zilles, K., 1999. Broca’s region revisited: cytoarchitecture and intersubject variability. *J. Comp. Neurol.* 412 (2), 319–341. [https://doi.org/10.1002/\(sici\)1096-9861\(19990920\)412:2<319::aid-cne10>3.0.co;2-7](https://doi.org/10.1002/(sici)1096-9861(19990920)412:2<319::aid-cne10>3.0.co;2-7). PMID: 10441759.
- Ayesu, K., Nguyen, B., Harris, S., Carlan, S., 2018. The case for consistent use of medical eponyms by eliminating possessive forms. *J. Med. Libr. Assoc.* 106 (1), 127–129. <https://doi.org/10.5195/jmla.2018.284>.
- Boraud, T., Forkel, S.J., 2022. Paul Broca: from fame to shame? *Brain* 145 (3), 801–804. <https://doi.org/10.1093/brain/awab444>.
- Bresch, D., 2002. Beyond Wernicke’s: a lexicon of eponyms in psychiatry. *J. Neuropsychiatr. Clin. Neurosci.* 14 (2), 155–160. <https://doi.org/10.1176/jnp.14.2.155>.
- Burdan, F., Dworżański, W., Cendrowska-Pinkosz, M., Burdan, M., Dworżańska, A., 2016. Anatomical eponyms—unloved names in medical terminology. *Folia Morphol.* 75 (4), 413–438. <https://doi.org/10.5603/FM.a2016.0012>.
- Catani, M., Forkel, S.J., Thiebaut de Schotten, M., 2010. Asymmetry of white matter pathways in the brain. In: Hugdahl, K., Davidson, R.J. (Eds.), *Two halves of the brain: Information processing in the cerebral hemispheres*. MIT Press.
- Catani, M., Jones, D.K., Donato, R., Ffytche, D.H., 2003. Occipito-temporal connections in the human brain. *Brain* 126 (Pt 9), 2093–2107. <https://doi.org/10.1093/brain/awg203>. Epub 2003 Jun 23. PMID: 12821517.
- Catani, M., Jones, D.K., Ffytche, D.H., 2005. Perisylvian language networks of the human brain. *Ann. Neurol.* 57 (1), 8–16. <https://doi.org/10.1002/ana.20319>. PMID: 15597383.
- Catani, M., Mesulam, M.M., Jakobsen, E., Malik, F., Martersteck, A., Wieneke, C., Thompson, C.K., Thiebaut de Schotten, M., Dell’Acqua, F., Weintraub, S., Rogalski, E., 2013. A novel frontal pathway underlies verbal fluency in primary progressive aphasia. *Brain* 136 (Pt 8), 2619–2628. <https://doi.org/10.1093/brain/awt163>. Epub 2013 Jul 2. PMID: 23820597; PMCID: PMC3722349.

- Catani, M., Thiebaut de Schotten, M., 2008. A diffusion tensor imaging tractography atlas for virtual in vivo dissections. *Cortex* 44 (8), 1105–1132. <https://doi.org/10.1016/j.cortex.2008.05.004>. Epub 2008 May 23. PMID: 18619589.
- Catani, M., Thiebaut de Schotten, M., 2012. Atlas of Human Brain Connections. OUP, Oxford. <https://doi.org/10.1093/med/9780199541164.003.0073>.
- Chrzanowska, K.H., Gregorek, H., Dembowska-Bagińska, B., Kalina, M.A., Digweed, M., 2012. Nijmegen breakage syndrome (NBS). *Orphanet J. Rare Dis.* 7, 13. <https://doi.org/10.1186/1750-1172-7-13>.
- Curran, E.J., 1909. A new association fiber tract in the cerebrum with remarks on the fiber tract dissection method of studying the brain. *J. Comp. Neurol. Psychol.* 19 (6), 645–656. <https://doi.org/10.1002/cne.920190603>.
- Duffau, H., Gatignol, P., Mandonnet, E., Peruzzi, P., Tzourio-Mazoyer, N., Capelle, L., 2005. New insights into the anatomo-functional connectivity of the semantic system: a study using cortico-subcortical electrostimulations. *Brain* 128 (Pt 4), 797–810. <https://doi.org/10.1093/brain/awh423>.
- Dziedzic, T.A., Balasa, A., Jezewski, M.P., Michałowski, Ł., Marchel, A., 2021. White matter dissection with the Klingler technique: a literature review. *Brain Struct. Funct.* 226 (1), 13–47.
- Eycleshmer, A.C., 2018. Anatomical Names: Especially the Basle Nomina Anatomica. Forgotten Books.
- Forkel, S.J., Thiebaut de Schotten, M., Kawadler, J.M., Dell'Acqua, F., Danek, A., Catani, M., 2014. The anatomy of fronto-occipital connections from early blunt dissections to contemporary tractography. *Cortex* 56, 73–84. <https://doi.org/10.1016/j.cortex.2012.09.005>.
- Forkel, S.J., Friedrich, P., Thiebaut de Schotten, M., Howells, H., 2022. White matter variability, cognition, and disorders: a systematic review. *Brain Struct. Funct.* 227 (2), 529–544. <https://doi.org/10.1007/s00429-021-02382-w>.
- Frigeri, T., Paglioli, E., de Oliveira, E., Rhoton Jr., A.L., 2015. Microsurgical anatomy of the central lobe. *J. Neurosurg. JNS* 122 (3), 483–498. <https://doi.org/10.3171/2014.11.JNS14315>.
- Giampiccolo, D., Duffau, H., 2022. Controversy over the temporal cortical terminations of the left arcuate fasciculus: a reappraisal. *Brain* 145 (4), 1242–1256. <https://doi.org/10.1093/brain/awac057>.
- Hagoort, P., 2019. The neurobiology of language beyond single-word processing. *Science* 366 (6461), 55–58. <https://doi.org/10.1126/science.aax0289>.
- Henrietta Lacks: science must right a historical wrong. 2020. *Nature*, 585 (7823), 7. <https://doi.org/10.1038/d41586-020-02494-z>.
- His, W., His, W., 1895. Die anatomische Nomenclatur. Nomina anatomica, Verzeichniss der von der anatomischen Gesellschaft auf ihrer IX. Versammlung in Basel angenommenen Namen. *Veit*. <https://doi.org/10.5962/bhl.title.44115>.
- Karenberg, A., 2013. The world of gods and the body of man: mythological origins of modern anatomical terms. *Anatomy* 6–7, 7–22. <https://doi.org/10.2399/ana.11.142>.
- Kucharz, E.J., 2020. Medical eponyms from linguistic and historical points of view. *Reumatologia* 58 (4), 258–260. <https://doi.org/10.5114/reum.2020.98440>.
- Mars, R.B., Foxley, S., Verhagen, L., Jbabdi, S., Sallet, J., Noonan, M.P., Neubert, F.-X., Andersson, J.L., Croxson, P.L., Dunbar, R.I.M., Khrapitchev, A.A., Sibson, N.R., Miller, K.L., Rushworth, M.F.S., 2016. The extreme capsule fiber complex in humans and macaque monkeys: a comparative diffusion MRI tractography study. *Brain Struct. Funct.* 221 (8), 4059–4071. <https://doi.org/10.1007/s00429-015-1146-0>.
- Matchin, W., den Ouden, D.-B., Hickok, G., Hillis, A.E., Bonilha, L., Fridriksson, J., 2022. The Wernicke conundrum revisited: evidence from connectome-based lesion-symptom mapping. *Brain* 145 (11), 3916–3930. <https://doi.org/10.1093/brain/awac219>.
- Matchin, W., Den Ouden, D.-B., Hickok, G., Hillis, A.E., Bonilha, L., Fridriksson, J., 2023. Reply: the Wernicke conundrum is misinterpreted. *Brain* 146 (4), e23–e24. <https://doi.org/10.1093/brain/awac483>.
- Mesulam, M.-M., Thompson, C.K., Weintraub, S., Rogalski, E.J., 2015. The Wernicke conundrum and the anatomy of language comprehension in primary progressive aphasia. *Brain* 138 (Pt 8), 2423–2437. <https://doi.org/10.1093/brain/aww154>.
- Mesulam, M., Thompson, C., Weintraub, S., Rogalski, E., 2022. The Wernicke conundrum is misinterpreted. *Brain* 146 (4), e21–e22. <https://doi.org/10.1093/brain/awac482>.
- Marecková, E., Simon, F., Cervený, L., 2001. On the new anatomical nomenclature. *Ann Anat* 183 (3), 201–207. [https://doi.org/10.1016/S0940-9602\(01\)80215-6](https://doi.org/10.1016/S0940-9602(01)80215-6). PMID: 11396787.
- Naznean, A., 2021. Deity, love, punishment, rage, and mythonyms from head to toes. A brief history of some medical terms. *Revista Romana de Medicina de Laborator* 29 (3), 327–331. <https://doi.org/10.2478/rrlm-2021-0023>.
- Oishi, K., Zilles, K., Amunts, K., Faria, A., Jiang, H., Li, X., Akhter, K., Hua, K., Woods, R., Toga, A.W., Pike, G.B., Rosa-Neto, P., Evans, A., Zhang, J., Huang, H., Miller, M.I., van Zijl, P., Mazziotta, J., Mori, S., 2008. Human brain white matter atlas: identification and assignment of common anatomical structures in superficial white matter. *NeuroImage* 43 (3), 447–457. <https://doi.org/10.1016/j.neuroimage.2008.07.009>.
- Ono, M., Kubik, S., Abernathy, C.D., 1990. Atlas of the Cerebral Sulci. G. Thieme Verlag; Thieme Medical Publishers. <http://books.google.com/books?id=L7tqAAAAMAAJ>.
- Pajevic, S., Pierpaoli, C., 1999. Color schemes to represent the orientation of anisotropic tissues from diffusion tensor data: application to white matter fiber tract mapping in the human brain. *Magn. Reson. Med.* 42 (3), 526–540. Erratum in: *Magn Reson Med* 2000 Jun;43(6):921. PMID: 10467297.
- Price, C.J., 2012. A review and synthesis of the first 20 years of PET and fMRI studies of heard speech, spoken language and reading. *NeuroImage* 62, 816–847. <https://doi.org/10.1016/j.neuroimage.2012.04.062>.
- Ribas, G.C., 2010. The cerebral sulci and gyri. *Neurosurg. Focus* 28 (2), E2. <https://doi.org/10.3171/2009.11.FOCUS09245>.
- Sakai, T., 2007. Historical evolution of anatomical terminology from ancient to modern. *Anat. Sci. Int.* 82 (2), 65–81. <https://doi.org/10.1111/j.1447-073X.2007.00180.x>.
- Schmahmann, J.D., Pandya, D.N., 2006. Fiber Pathways of the Brain. Oxford University Press. <https://doi.org/10.1093/acprof:oso/9780195104233.001.0001>.
- Schmahmann, J.D., Pandya, D.N., 2007. The complex history of the fronto-occipital fasciculus. *J. Hist. Neurosci.* 16 (4), 362–377. <https://doi.org/10.1080/09647040600620468>.
- Thiebaut de Schotten, M., Forkel, S.J., 2022. The emergent properties of the connected brain. *Science* 378 (6619), 505–510. <https://doi.org/10.1126/science.abq2591>.
- Tremblay, P., Dick, A.S., 2016. Broca and Wernicke are dead, or moving past the classic model of language neurobiology. *Brain Lang.* 162, 60–71. <https://doi.org/10.1016/j.bandl.2016.08.004>.
- Türe, U., Yaşargil, M.G., Friedman, A.H., Al-Mefty, O., 2000. Fiber dissection technique: lateral aspect of the brain. *J. Neurosurgery* 47 (2), 417–426. discussion 426-7. <https://doi.org/10.1097/00006123-200008000-00028>. PMID: 10942015.
- Yaşargil, G.M. *Microneurosurgery*, volume IV A: CNS tumors: surgical anatomy, neuropathology, neuroradiology, neurophysiology, clinical considerations, operability, treatment options. Thieme, 1994.